

Properties of honey: its mode of action and clinical outcomes

This article outlines the key actions of honey when used as a treatment for wounds and examines the evidence base for its efficacy and impact on clinical outcomes. It also provides a guide to the assessment of wounds in order to identify infection, to ensure that antimicrobial dressings such as honey are used appropriately. Finally, the Mesitran range of dressings (Aspen, Redditch) is described and individual case reports presented which demonstrate the use of these products in clinical practice.

Jackie Stephen Haynes, Rosie Callaghan

KEY WORDS

Clinical outcomes
Honey
Assessment
Antimicrobial properties

The real cost of tissue viability and infection management should be considered in human terms, as well as the financial costs to healthcare organisations. In hospitals in the UK, 9% of patients have a healthcare-associated infection (HCAI) and this is costing about £1bn every year (Department of Health [DH], 2005). Healthcare associated infections can result in a range of morbidity and mortality in vulnerable individuals (DH, 2008). A HCAI is one that the patient acquires in association with receiving healthcare and which was previously not evident (Wilson, 2006). Patients who are acutely ill in hospital are most likely to acquire a HCAI, but they can also affect patients

in other settings where healthcare is delivered, for example, GP surgeries, care homes and even the patient's own home (DH, 2008).

Both acute and chronic wounds, healing by primary or secondary intention, may result in a HCAI. Infection occurs as a result of the imbalance between the patient's immune system and the pathogens present. The impact is always significant and a cause for concern, clinically and financially. The adverse effects caused by pathogens invading and multiplying in tissues are recognised as the signs and symptoms of infection. Since the seminal article on chronic wound infection (Cutting and Harding, 1994), it has been recognised that a significant factor in the ability of the wound to heal is the ability to identify and manage infection. The European Wound Management Association (EWMA, 2005, 2006) and the World Union of Wound Healing Societies (WUWHS, 2008) offer advice on assessment and management of infection. A Best Practice statement (2010) also offers guidance on the use of topical antiseptic/antimicrobial agents in wound management.

Honey's role in wound care

Honey has been used for 2,000 years to treat wounds, and, while having a recent resurgence in popularity (Molan, 1999; Cooper, 2008), it still may not be given its deserved recognition. It is possible

that the use of an ancient remedy may be seen as a regressive rather than an innovative step within tissue viability (Bowler et al, 2001).

Therapeutic properties of honey

Honey may be a useful addition to the current range of products used in wound care due to its:

- ▶▶ Antimicrobial properties (Cooper and Molan, 1999; Cooper et al, 1999; Dunford et al, 2000; Thorne, 2005; Cooper, 2008)
- ▶▶ Ability to autolytically debride and deodorise (Stephen-Haynes, 2004; White and Molan, 2005)
- ▶▶ Anti-inflammatory properties (Tanaka et al, 1995)
- ▶▶ Ability to stimulate tissue growth (Molan, 2002; White and Molan, 2005)
- ▶▶ Ability to manage pain and minimise scarring (Stephen-Haynes, 2005; White and Molan, 2005).

Antimicrobial properties

Honey is a super-saturated solution of sugars with a low water content which binds water molecules, such as those present in wound exudate, making it unavailable for the microorganism. Microorganisms require nutrients such as carbon, nitrogen, minerals and water and any restriction in availability will compromise their metabolism. The acidity of honey (pH 3.4–6.1) also helps to restrict microbial growth (Molan, 1999).

Jackie Stephen-Haynes is Consultant Nurse and Senior Lecturer in Tissue Viability for Worcestershire Primary Care Trusts and University of Worcester; Rosie Callaghan is Tissue Viability Specialist Nurse in nursing homes, Worcestershire PCT

The antimicrobial properties of honey are also thought to be a result of its ability to generate hydrogen peroxide, a well-known antimicrobial agent (Molan, 2005). When honey comes into contact with wound exudate, it is diluted and this activates the enzyme glucose oxidase to produce low, non-toxic levels of hydrogen peroxide.

The antimicrobial action of honey is effective against common wound-infecting organisms such as *Pseudomonas aeruginosa*, *Staphylococcus aureus*, *Candida albicans* and *Escherichia coli*. Significantly, honey can be effective against antibiotic-resistant strains of bacteria (Cooper and Molan, 1999; Cooper et al, 1999; Dunford et al, 2000; Thorne, 2005; Cooper, 2008). This is particularly important considering the rise in antibiotic resistance. Vandeputte and Van Waeyenberge (2003) reporting *in vitro* research on Mesitran S identified that it was effective against a range of bacterial levels. Stobberingh (2010) reported *in vitro* research on Mesitran and Mesitran S using antibiotic-resistant clinical isolates and extended-spectrum beta-lactamase (ESBL) strains of bacteria. The research showed that both products were effective (Stobberingh, 2010).

Moore (2001) examined eight randomised controlled trials investigating the effect of honey on wound healing and found the majority of trials demonstrated significantly better outcomes with honey. White and Molan (2005) also found a range of positive outcomes in their summary of the published clinical research. They found that the topical application of honey has been reported to clear existing wound infection rapidly, facilitate healing of deeply infected surgical wounds and halt spreading necrotising fasciitis. It has also promoted healing in infected wounds that were not responding to conventional therapy, such as antibiotics and antiseptics, including wounds that were infected with antibiotic-resistant bacteria such as methicillin-resistant *Staphylococcus aureus* (MRSA).

Molan (2006) reporting from 17 randomised controlled trials involving

a total of 1965 participants, and five clinical trials of other forms involving 97 participants treated with honey, observed the positive impact that honey had on patients, and its effectiveness in assisting wound healing. However, Jull et al (2008) found no benefit in relation to healing using honey as an adjunct to compression therapy in venous ulceration. However, healing may not be the only outcome and the impact on debridement, odour or pain management was not discussed. Kingsley (2001) also reported two case reports where honey failed to eliminate infection, and Alcaraz and Kelly (2002) similarly described a case in which honey failed to eradicate bacteria from a chronic wound. However, Alcaraz and Kelly (2002) did note an improvement in wound exudate and odour.

The tendency of a wound to become infected and the opportunity for pathogens to proliferate and colonise the wound bed and impair healing is influenced by:

- ▶▶ The severity of the lesion
- ▶▶ The age and state of health of the patient
- ▶▶ The nutritional status of the patient
- ▶▶ The patient's ability to mount an immune response.

Clinicians should consider these factors carefully when choosing treatment options. Cooper et al (1999) reported that honey that had been diluted 7–14 times continued to prevent the growth of *S. aureus*. However, the high osmolarity of honey may be reduced in the presence of copious exudate until it can no longer inhibit infection (Molan, 2001). Also, it is important to remember that the potency of antibacterial factors varies as much as a hundred-fold from honey to honey (Molan, 2002). Honey dressings should therefore be evaluated in clinical practice to establish efficacy and on which wound types they are most beneficial.

Deodorising and debriding

Malodour is a common feature of chronic wounds and is attributed to the presence of anaerobic bacterial species that produce malodorous compounds

from decomposed serum and tissue proteins (Bowler et al, 2001). It is probably more than just antimicrobial action that is responsible for the rapid deodorising of wounds that is observed when honey dressings are used. Honey provides a rich source of glucose that bacteria metabolise in preference to amino acids, resulting in the production of a non-odorous metabolite, lactic acid (White and Molan, 2005).

Honey facilitates the debridement of wounds by the autolytic action of tissue proteases. It creates a moist wound environment by drawing out lymph fluid from the wound tissues through its strong osmotic action. This provides a constant supply of proteases at the interface of the wound bed and the overlying necrotic tissue, that may help to explain the rapid debridement brought about by honey. This action also washes the surface of the wound bed from beneath, explaining the frequent observations that honey dressings remove debris such as foreign bodies with the dressing (Molan, 2002), and the painless lifting off of slough and necrotic tissue (Subrahmanyam, 1998). The activation of proteases by hydrogen peroxide liberated by honey may also offer an explanation for the observed rapid debridement (White and Molan, 2005).

Honey is known to deodorise wounds rapidly (White and Molan, 2005). Van der Weyden (2003) reported that the use of honey alginate on patients with pressure ulcers led to quick and complete healing, as well as having a deodorising and anti-inflammatory effect. Similarly, Stephen-Haynes (2004) reported upon clinical cases where the use of honey resulted in the debridement of wounds in three patients and the management of odour in five patients. There is clearly a need for the control of malodorous wounds within primary care, particularly with pressure ulcers, and honey has proven effective at achieving this goal (Scanlon and Stubbs, 2002; Booth, 2003). In addition, Hampton (2004) identified the importance of the control of malodour with patients with fungating wounds and recognised the role that honey could play in treating these patients.

This debriding action of a honey dressing may also contribute to the lowering of a wound's bacterial load by removal of dead tissue. Dead tissue is well known to provide an excellent medium for bacterial growth and increase the risk of infections if left in the wound (Leaper, 2002).

Anti-inflammatory properties and the stimulation of new tissue growth

The body's inflammatory response marks the beginning of the healing process, but a prolonged reaction can inhibit healing, causing further damage to the tissues and making it harder to manage the wound. A prolonged inflammatory response is often associated with high levels of exudate. Suppressing inflammation, as well as reducing pain for the patient, reduces the opening of blood vessels, thus lessening oedema and exudate. It is thought that the ability of honey to clear infection and debride wounds contributes to its anti-inflammatory action. The mechanism by which honey reduces excessive inflammation is not known, although it has been suggested that it may be linked to the antioxidants in honey mopping up free radicals (Molan, 2005).

Molan (2005) notes that prolonged inflammation causes fibrosis that manifests as hypertrophic scarring in wounds. Topham (2002) showed that honey could reduce scarring by illustrating its effect on the extracellular matrix. Marshall (2002) reported the anti-inflammatory effectiveness of honey in podiatry and Templeton (2002) reported that the reduction of inflammation, the promotion of angiogenesis and the formation of granulation tissue is stimulated by honey. Honey has also been reported to stimulate the growth of epithelium (Subrahmanyam, 1998). This production of new tissue is commonly associated with the use of honey dressings and Dunford et al in a small-scale study (2000) also reported significant epithelialisation when using honey.

Pain management and reduction in scarring

While several clinical outcomes that have been reported in relation to

the use of honey are attributed to its therapeutic mechanisms, the management of pain (Molan, 1999; 2002; White and Molan, 2005) (although some patients complain of stinging or drawing sensation) (Pieper, 2009) and minimising scarring are also reported (Dunford et al, 2000; Molan, 2001; Stephen-Haynes, 2005).

A study carried out on patients with burns has shown that application of antioxidants to mop up free radicals reduces inflammation (Tanaka et al, 1995). Honey has a significant content of antioxidants that perform this function (Frankel et al, 1998), and this may account for the fact that honey dressings prevent partial-thickness burns from converting to full-thickness burns requiring plastic surgery (Subrahmanyam, 1998).

Assessment of wounds and identifying infection

By accurately assessing the wound, the primary objective of wound management can be determined and the specific mode of application of honey can be decided in an informed and considered way. Wound Bed Preparation (WBP) has become an increasingly accepted term, and its implementation has been aided by the concept of the acronym TIME. This has been developed by an international advisory panel and offers a structured approach to the implementation of WBP and the management of chronic wounds (Schultz et al, 2003). TIME incorporates assessment and management and relates clinical observations and interventions to the cellular level (Dowsett and Ayello, 2004), as does Applied Wound Management (AWM) (Gray et al, 2005). It is anticipated that such systematic approaches will lead to rational decisions in the management of patients with chronic wounds. From a clinical management perspective, it is the recognition of the state of the wound with respect to infection status that is particularly challenging.

Infection/inflammation

The signs of inflammation are pain, tenderness, redness, erythema and, if prolonged, this indicates infection

(Cutting and Harding, 1994). Cutting et al (2005) listed the criteria for identifying infection in patients with different types of wounds using a Delphi panel (EWMA, 2005). Early recognition of wound infection, or those susceptible to infection, is a cornerstone of effective wound management.

Healing, or the prevention of infection, depends on creating or restoring the balance between the host's defence mechanisms and the number of pathological organisms that occur in the wound environment (Gray et al, 2005a). Wounds healing by secondary intention are often colonised by multiple organisms without resulting in wound infection. It is important to remember that in wounds healing by secondary intention, colonisation is the 'healthy' situation (Edwards and Harding, 2004). Colonised wounds often heal without the need for antimicrobial intervention because the host immune response is adequate on its own (Leaper, 1994). Critical colonisation is the point at which bioburden delays wound healing. Clinical management of these wounds needs a topical, sustained release antimicrobial dressing, such as honey (Gray et al, 2005a). Infected wounds increase pain levels and are detrimental to the patient's health and contribute to a deterioration of the patients' general condition.

White (2002) suggested that the quantification of microbes representing colonisation, critical colonisation and infection are not exact states and are influenced by the host's immune response. Those who are at significant risk of an infection may benefit from the use of an antimicrobial dressing, but standard prophylactic use of antimicrobial agents, like antibiotics, should be avoided.

Clinicians have a professional responsibility to accurately and promptly recognise the signs of infection and to instigate and monitor treatment. The Wound Infection Continuum offers a systematic approach, with the aim of moving the wound from infection to colonisation (Figure 1) (Gray et al, 2005b).

Honey dressings

Honey dressings can be used for several purposes, including:

- ▶▶ Attempting to optimise patient comfort and mobility
- ▶▶ Managing moderate to severe exudate and excessive fluid
- ▶▶ Protecting granulation tissue and managing infections — notably *P. aeruginosa*, *S. aureus*, *C. albicans*, *E. Coli* and meticillin and vancomycin-resistant strains.

Correction of the bioburden diminishes inflammation in the wound bed, while enhancing the proliferative phases of repair (Falanga, 2000). Honey dressings can assist in infection control by reducing the number of pathogens to a level where the host is able to provide protection, or the level of pathogens is reduced to prevent cross-infection (Cooper, 2008).

Honey dressings should be used until the wound shows signs of healing and then may be discontinued. The use of antimicrobial dressings should be limited to four weeks if no improvement is noted (Best Practice Statement, 2010). A thorough reassessment should be undertaken to identify factors that could lead to delayed healing. Addressing the underlying molecular and cellular imbalance that may be responsible for indolence is increasingly recognised as essential in providing chronic wound care within primary care (EWMA, 2008).

Mesitran products

The Mesitran range of dressings is designed to cope with a variety of wound types. Mesitran Ointment and Mesitran Ointment S are suitable for wounds that are sloughy, possibly malodorous, and critically colonised (Stobberingh, 2010). The ointment has been proven to stimulate angiogenesis at a non-toxic level (Rossiter, 2010).

Mesitran is also available as a honey/hydrogel sheet. This is again useful for wounds that require moisture, while also providing the antimicrobial benefits of a honey-based product to help reduce wound bioburden and promote tissue regeneration (Du Toit and Page, 2009).

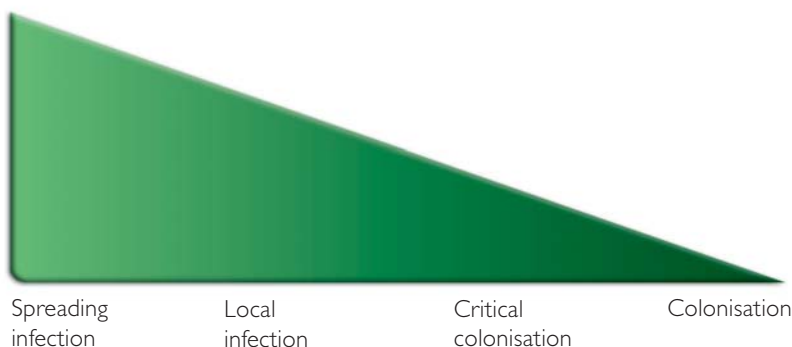


Figure 1. The Wound Infection Continuum.

Honey dressings can assist in infection control by reducing the number of pathogens to a level where the host is able to provide protection, or the level of pathogens is reduced to prevent cross-infection (Cooper, 2008).

Mesitran Mesh is a non-adherent dressing that can introduce small levels of honey to superficial wounds, such as grazes and skin tears, and allows exudate to pass through in wetter wounds. The Mesitran range and the components of each product are described in Table 1.

Clinical use of Mesitran

The following case reports demonstrate the properties of Mesitran and its use on a range of wound types.

Skin tears

There are several reasons for the development of skin tears/lacerations, with the most common causes being friction, combined shearing forces, direct trauma and intrinsic skin changes. The layers of skin start to atrophy and the epidermis becomes thin and fragile with age, and dermal thickness decreases by 20% with reduced elasticity (White et al, 1995). Skin tears are identified as being more common in older women (Baranoski, 2003).

The patient in this case was an 83-year-old woman living in a nursing home for older people with mental health problems. She had diagnoses of polymyalgia rheumatica, osteoporosis and dementia. She had a lack of spatial awareness and had thin steroidal skin following many years of steroid treatment. She needed a Zimmer frame to move around and sustained a tear to her right leg while walking. She was taken to A&E and the wound was

Table 1
Mesitran product range

▶▶ Mesitran Ointment	Ointment containing 48% medical grade honey, presented in a tube
▶▶ Mesitran Ointment S	Gel containing 40% medical grade honey, presented in a tube
▶▶ Mesitran and Mesitran Border	Hydrogel sheet dressing containing 30% medical grade honey, with or without adhesive borders
▶▶ Mesitran Mesh	Primary wound contact layer containing 20% medical grade honey

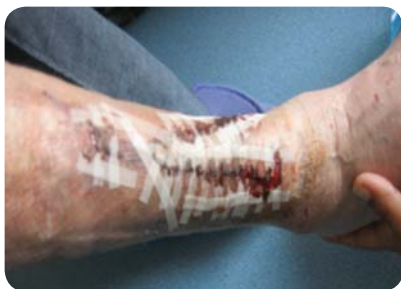

Figure 2. Skin tear following initial treatment in A&E.

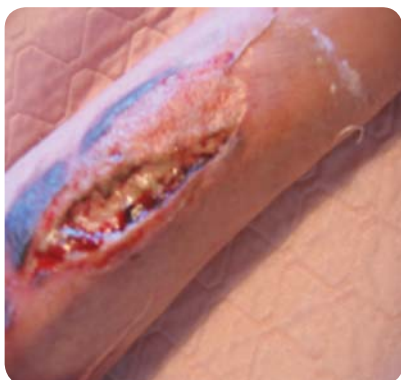

Figure 3. Necrotic tissue in the wound seven days after initial treatment.

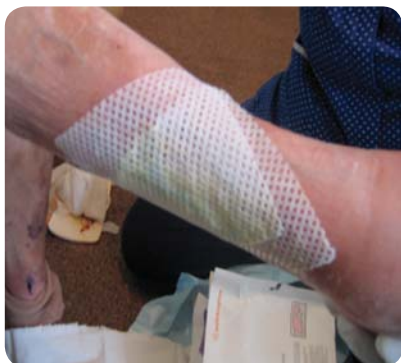

Figure 4. Mesitran Mesh used to treat skin tear.

sutured with numerous Steri-strips, a pad and bandage (Figure 2).

Due to the swelling of the wound, the Steri-strips became tight and the skin flap became necrotic seven days later (Figure 3).

An assessment was undertaken with the TIME wound management tool in mind, and both tissue (T) and infection (I) were identified as a focus for care. Mesitran Mesh was applied (Figure 4) to assist in debriding the wound and preventing infection. This

treatment choice also allowed for infrequent dressing changes, reducing the need to expose the wound bed as this was distressing for the patient. The dressing was left in place for five days with Mesitran Ointment applied daily. After seven days, 75% of the wound had debrided and once completed the mesh was used alone until total healing was almost achieved. The second dressing remained in place for five days. At review on day 5, the wound was clean and healthy with signs of epithelialisation taking place. In the third week, the wound had halved in size and continued to heal quickly.

When two small areas remained, the patient refused treatment as she felt the leg was much better. The area scabbed like a graze and eventually healed.

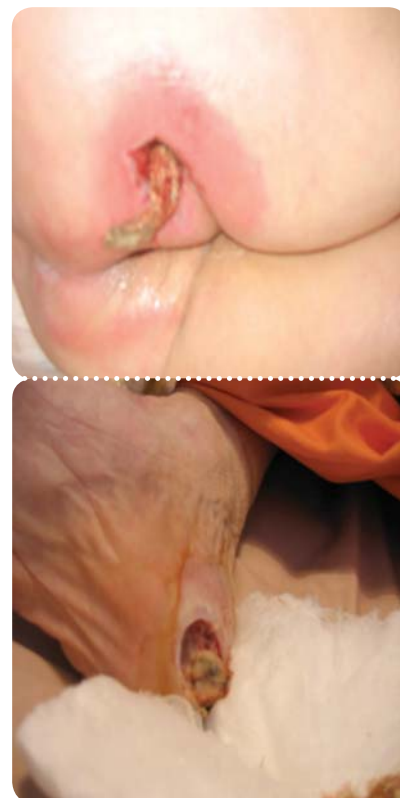
In the authors' experience, skin tears appear to respond well to treatment with Mesitran Mesh. It has been used effectively within the care home sector at Worcestershire Primary Care Trust, particularly for those clients who have an increased risk of infection or who have previously been colonised with MRSA. Further research exploring both the clinical and microbiological impact of Mesitran Mesh on patients with skin tears is essential to support this product's use in clinical practice.

Pressure ulcers

The authors have found Mesitran to be effective at debriding grade 3–4 pressure ulcers (European Pressure Ulcer Advisory Panel [EPUAP], 2009). It works by softening necrotic tissue and entering the wound around the edges. The necrotic tissue appears to 'core' and remains intact, enabling removal as a large single piece of necrotic tissue (Figures 5 and 6). This process could be speeded up with sharp debridement.

Mesitran's anti-inflammatory effect

A 45-year-old woman presented with an area of redness secondary to a suspected insect bite on the left lower leg (Figure 7). Mesitran Ointment was applied twice daily to the area. The pain rating was moderate and the area was described as irritating.



Figures 5 and 6. Sacral pressure ulcer (top), where Mesitran has been effective at softening necrotic tissue, enabling it to be removed as one single piece (bottom).

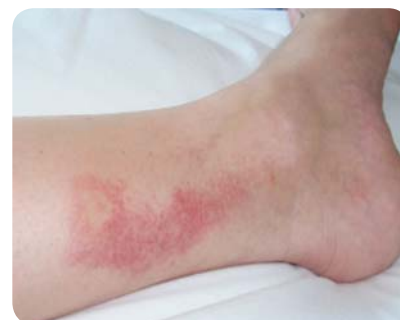

Figure 7. Irritation secondary to possible insect bite.

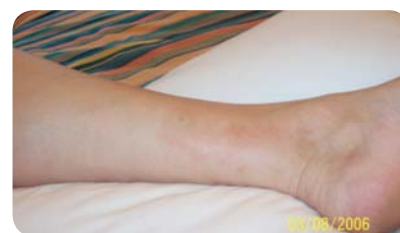

Figure 8. Three days after treatment.

The significant anti-inflammatory effect could be seen within three days

and the irritation resolved quickly (Figure 8).

Use of Mesitran for odour management

This case involved a patient with a fungating wound. A Mesitran hydrogel sheet was applied so that the patient could benefit from its odour-managing properties. It was a comfortable dressing and the patient reported a significant decrease in odour.

Practical tips for the use of honey dressings

Molan (2002) identified a reference guide for the use of honey dressings in practice that can be applied to the Mesitran range:

- ▶▶ Do not leave it too late to start using honey on a wound
- ▶▶ Use only honey that has been selected for use in wound care
- ▶▶ Use dressings that will hold a sufficient amount of honey in place on the wound in order to obtain a good therapeutic effect
- ▶▶ Ensure that honey is in full contact with the wound bed
- ▶▶ If a non-adherent dressing is used between the honey dressing and the wound bed, it must be sufficiently porous to allow the active components of the honey to diffuse through
- ▶▶ Ensure that honey dressings extend to cover any area of inflammation surrounding wounds
- ▶▶ Use a suitable secondary dressing to prevent leakage of honey
- ▶▶ Change the dressings frequently enough to prevent the honey being washed away or excessively diluted by wound exudate
- ▶▶ When using honey to debride hard eschar, scoring and softening the eschar by soaking with saline will allow better penetration of the honey.

Within clinical practice at the author's primary care trust (PCT), the above guidance has been adopted and many evaluations have been completed with positive clinical outcomes in wound healing, infection prevention and control, and in anti-inflammatory, scar and odour management.

Conclusion

A systematic approach to wound assessment, the identification of infection and an increasing range of antimicrobial dressings can increase opportunities for clinicians to assist positively with patient care. Dressing wounds with honey was historically standard practice, but went out of fashion when antibiotics came into common usage. Now that antibiotic-resistant bacteria have become a widespread clinical problem, there has been a renaissance in the use of topical antiseptic/antimicrobial agents in wound management, including honey.

Laboratory studies and clinical trials have shown that honey is an effective broad-spectrum antimicrobial agent, which does not have an adverse effect on wound tissues (Vandeputte and Van Waeyenberge, 2003; Stobberingh, 2010). Several studies have also shown that as well as having an antimicrobial action, honey has other activities that are beneficial to the wound healing process (Dunford et al, 2000; Vandeputte and Van Waeyenberge, 2003; Thorne, 2005; Stobberingh, 2010). It enables rapid autolytic debridement, deodorises wounds, and stimulates the growth of wound tissue. Its anti-inflammatory activity reduces pain, oedema and exudate and minimises hypertrophic scarring.

Honey provides a moist healing environment for wound tissue with no risk of maceration of the surrounding skin, and completely prevents adherence of dressings to the wound bed so that there is no pain and no tissue damage when dressings are changed. Molan (2006) concluded that there is a significant body of evidence to support the clinical use of honey, and Cooper (2008) extols the value of honey microbiologically. The increasing number of publications of clinical trials and reports of clinical experience should ensure that honey is not sidelined as an 'alternative' medicine. It is an established approach to wound management that has been out of common use for half a century but which has now been 'rediscovered', offering clinicians the opportunity to achieve positive clinical outcomes. **WUK**

Key points

- ▶▶ Healthcare associated infections (HAIs) can result in a range of morbidity and mortality in vulnerable individuals (DH, 2008).
- ▶▶ Early recognition of wound infection, or those susceptible to infection, is a cornerstone of effective wound management.
- ▶▶ Honey dressings enable rapid autolytic debridement, deodorise wounds, and stimulate the growth of wound tissues. Their anti-inflammatory activity rapidly reduces pain, oedema and exudate and minimises hypertrophic scarring.

References

Alcaraz A, Kelly J (2002) Treatment of an infected venous leg ulcer with honey dressings. *Br J Nurs* 11(13): 859–66

Baranoski S (2003) Skin tears: Staying on guard against the enemy of frail skin. *Nurs Management* 32: 25–32

Best Practice Statement (2010) *The use of topical antiseptic/antimicrobial agents in wound management*. Wounds UK, Aberdeen

Booth S (2003) Are honey and sugar paste alternatives to topical antiseptics. *J WoundCare* 13(1): 31–3

Bowler P, Duerden B, Armstrong D (2001) Wound microbiology and associated approaches in wound management. *Clin Micro Rev* 14(2): 244–69

Cooper R (2008) Using honey to inhibit wound pathogens. *Nurs Times* 104(3): 46–9

Cooper R, Molan PC, Harding KG (1999) Antibacterial activity of honey against strains of *Staphylococcus aureus* from infected wounds. *J R Soc Med* 92: 283–5

Cooper R, Molan P (1999) The use of honey as an antiseptic in managing pseudomonas infection. *J wound Care* 8(4): 161–4

Cutting K, Harding K (1994) Criteria for

- identifying wound infection. *J Wound Care* 3(4): 198–201
- Cutting K, White R, Mahoney P, Harding K (2005) Clinical identification of wound infection: a Delphi approach. In: Position Document: *Pain at wound dressing changes*. MEP, London: 6–9
- Davies P (2005) Recent clinical usage of honey in the treatment of wounds. In: Natural approaches to wound management: A focus on honey and honey based dressings. Wounds UK supplement 1(3): 14–21
- Department of Health (2005) *Saving Lives: a delivery programme to reduce healthcare associated infection including MRSA*. DH, London. Available online at: www.dh.gov.uk/reducingmrsa
- Department of Health (2008) *Clean, safe care. Reducing infections and saving lives*. DH, London
- Dowsett C, Ayello E (2004) TIME principles of chronic wound bed preparation and treatment. *Br J Nurs (Tissue Viability supplement)* 13(15): s16–21
- Dunford C, Cooper R, Molan P, White (2000) The use of honey in wound management. *Nurs Standard* 15(11): 63–8
- Du Toit DF, Page B (2009) An *in vitro* evaluation of the cell toxicity of honey and silver dressings. *J Wound Care* 18(9): 383–9
- Edwards R, Harding KG (2004) Bacteria and wound healing. *Curr Opin Infect Dis* 17(2): 91–6
- European Pressure Ulcer Advisory Panel (2009) Pressure ulcer prevention and treatment guidelines. EPUAP, Available online at: www.epuap.org
- European Wound Management Association (2005) Position Document: *Identifying criteria for wound infection*. MEP Ltd, London
- European Wound Management Association (2006) Position Document: *Management of infection*. MEP Ltd, London
- European Wound Management Association (2008) Position Document: *Hard-to-heal wounds: a holistic approach*. MEP Ltd, London
- Falanga V (2000) Classifications for wound bed preparation and stimulation of chronic wounds. *Wound Rep Regen* 8(5): 347–52
- Frankel S, Robinson GE, Berenbaum MR (1998) Antioxidant capacity and correlated characteristics of 14 uni floral honeys. *J Apicultural Res* 37(1): 27–31
- Gray D, White RJ, Cooper P, Kingsley AR (2005b) Understanding applied wound management. *Wounds UK* 1(1): 62–8
- Gray D, White R, Cooper P, Kingsley A (2005b) Applied Wound Management. In: Gray D, Cooper P, eds. *Wound Healing: a systematic approach to advanced wound healing and management*. Wounds UK, Aberdeen
- Hampton S (2004) Managing symptoms of fungating wounds. *J Comm Nurs* 18(10): 22–8
- Jull A, Walker N, Parag V, Molan P, Rodgers A (2008) Honey as adjuvant leg ulcer therapy trial collaborators. Randomized clinical trial of honey-impregnated dressings for venous leg ulcers. *Br J Surg* 95(2): 175–82
- Kingsley A (2001) The use of honey in the treatment of infected wounds: case studies. *Br J Nurs* 22(10): 12–20
- Leaper D (1994) Prophylactic and therapeutic role of antibiotics in wound care. *Am J Surg* 167(1A): 155–205
- Leaper D (2002) *Sharp technique for wound debridement*. World wide wounds. Available online at: www.worldwidewounds.com/2002/december/Leaper/Sharp-Debridement.html
- Marshall C (2002) The use of honey in wound care: a review article. *Br J Podiatry* 5(2): 47–9
- Molan P (1999) The role of honey in the management of wounds. *J Wound Care* 8(8): 415–18
- Molan P (2001) Honey for the treatment of burns and wounds. *New Ethical J* July: 1–16
- Molan P (2002) Re-introducing honey in the management of wounds and ulcers: theory and practice. *Ostomy Wound Management* 48(11): 28–40
- Molan P (2005) Mode of action. In: White R, Cooper R, Molan P. *Honey: A Modern Wound Management Product*. Wounds UK Publications, Aberdeen
- Molan P (2006) The evidence supporting the use of honey as a wound dressing. *Int J Lower Extremity Wounds* 5(1): 40–54
- Moore AO, et al (2001) Systematic review of the use of honey as a wound dressing. *BMC Complementary and Alternative Medicine* 1: 2
- Pieper B (2009) Honey-based dressings and wound care: an option for care in the United States. *J Wound Ostomy Continence Nurs* 36(1): 60–6
- Rossiter K, Cooper AJ, Voegeli D, Lwaleed BA (2010) Honey promotes angiogenic activity in the rat aortic ring assay. *J Wound Care* 19(10): 440–6
- Scanlon E, Stubbs N (2002) To use or not to use? The debate on the use of antiseptics in wound care. *Br J Comm Nurs* 7(9)(suppl): s8–20
- Schultz G, Sibbald G, Falanga V, et al (2003) Wound bed preparation: a systematic approach to wound management. *Wound Repair Regen* 11(2): 1–28
- Stephen-Haynes J (2004) Evaluation of honey impregnated tulle dressing in primary care. *Br J Comm Nurs Wound care suppl* June: 21–7
- Stephen Haynes J (2005) Implications of honey dressings within primary care. In: Molan P, Cooper R, White R, eds. *Honey: A Modern Wound Management Product*. Wounds UK, Aberdeen: Chapter 3
- Stobberingh EE (2010) Antibacterial activity of honey against ESBL-producing strains. Report by the department of Medical Microbiology, data on file with the author
- Subrahmanyam M (1998) A prospective randomised clinical and histological study of superficial burn wound healing with honey and silver sulfadiazine. *Burns* 24(2): 157–61
- Tanaka H, Hanumadass M, Matsuda H, Shimazaki S, Walter RJ, Matsuda T (1995) Haemodynamic effects of delayed initiation of antioxidant therapy (beginning two hours after burn) in extensive third-degree burns. *J Burn Care Rehab* 16(6): 610–15
- Templeton S (2002) A review of the use of honey in wounds. *ACCNS J Community Nurses* 7(1): 13–14
- Thorne L (2005) *Use of Mesitran ointments and dressings in the management of multiple skin lesions of a patient with meningococcal septicaemia*. Poster presentation. Wounds UK conference, Harrogate
- Topham J (2002) Why do some cavity wounds treated with honey or sugar paste heal without scarring? *J Wound Care* 11(2): 53–5
- Vandeputte J, Van Waeyenberge P (2003) Clinical evaluation of L-Mesitran — a honey based wound ointment. *Eur Wound Manage J* 3(2): 8–11
- Van der Weyden (2003) The use of honey for the treatment of two patients with pressure ulcers. *Br J Comm Nurs* Dec: S14–20
- White M, Kaaram S, Cowell B (1995) Skin tears in frail elders: a practical approach to prevention. *Geriatr Nurs* 15(2): 95–9
- White R (2002) The wound infection continuum. Clinical review. The Silver supplement. *Br J Nurs* 11(22) and *Br J Community Nurs* 7(12): 7–9
- White R, Cooper R, Molan P (2005) *Honey: A Modern Wound Management Product*. Wounds UK, Aberdeen
- White R, Molan P (2005) A summary of published clinical research on honey in wound management. In: White R, Cooper R, Molan P. *Honey: A Modern Wound Management Product*. Wounds UK Publications, Aberdeen
- Wilson J (2006) *Infection Control in Clinical Practice*. 3rd edn. London: Bailliere Tindall
- World Union of Wound Healing Societies (2008) Principles of best practice: *Wound Infection in clinical practice*. An international consensus. MEP, London