

Reducing Antibiotics and avoiding Amputations in Diabetic Foot Ulcers with Honey Based Products

Authors: Dr HariKrishna. R, MD, Shahanisah Ahmad, RN , Noor Hayati Arbi, RN , Diabetic Foot Clinic, Kuala Lumpur general Hospital, Malaysia. November 25, 2009 - HKL, Kuala Lumpur, Malaysia

Introduction

The reported prevalence of Diabetes Mellitus (DM) in Malaysia was 14% in 2006. It is estimated that 15% to 20% of diabetics will be hospitalized with a foot complication at some point in time during the course of their disease and 12-24% of affected individuals with foot ulcers require amputation (Muhammad, 2008). A retrospective review of amputations in Malaysia showed that 66% of all the amputations were DM related. 80% of amputations were below the knee, the majority of the patients less than 60 years old (Yusof, 2007).

Considering the the high risk of amputations and worldwide growing resistance against antibiotics, the HKL Diabetic Foot Clinic has undertaken an evaluation of a novel wound care treatment based on honey for the management of complicated infected DM ulcers.

Methods

Six patients with infected ulcers below the left knee were treated with the honey based products L-Mesitran® (Triticum, Holland). At the start of the treatment wound culture swabs were taken following standard hospital protocol, the swabs were analysed in the hospital laboratory for the presence of pathogens and susceptibility to antibiotics. Recorded were wound size, malodour, previous treatments and patient medical history. Wounds were photographed at the start as a baseline measurement.

The primary endpoint was the removal of infection. The prevention of amputation was among the secondary endpoints which have been collated in figure 1.

Wounds were first cleaned with saline or a superoxidated solution (Dermacyn, Oculus) after which the honey product was applied directly on the wound bed. The honey products were applied following the manufacturers instructions. Thereafter the wound was covered with a suitable secondary dressing, based upon the needs of the wound and in accordance with the clinical investigators assessment. When the infection was not systemic, no antibiotics were used. Dressing changes were done either at the clinic or patients were instructed to perform dressing changes at home. In the hospital or at outpatient visits wound progress was recorded and photographed. During the treatment blood glucose levels were either monitored by the patient himself or at least at every outpatient visit. Patients were informed and they all provided written consent to participate in this evaluation.

Results and discussion

In each case, except one, the infection could be controlled without the use of antibiotics. In four cases the wound reduction was considerable (40%-95%). Amputation was prevented in the four indicated cases. The products were easy to apply and provided great patient comfort.

No pain was recorded during application and the dressings were easy to apply and remove. The high sugar content of the honey did not influence the blood glucose levels of the patients.

This 4,000 year old honey therapy (Dunford, 2000) has been neglected for a long time and only in the past few decades it was found that the honey should be sterile and free from residues, because honey often can contain, apart from non-pathogenic *Bacillus spp.*, clostridial spores (Postmes, 1993); supermarket honey therefore can not be used in wound care (Cooper, 2009). The use of honey therapy in for DM foot ulcers is safe (Shukrimi, 2008) and can be attributed to its antibacterial activity to rapidly clear infection, it provides a moist healing environment and debrides wounds (Molan, 2006). Furthermore: honey products promote new tissue regeneration or healing. They stimulate the keratinocytes and fibroblasts, essential to wound healing (Du Toit, 2009).

Conclusion

In this evaluation the L-Mesitran honey-based products have demonstrated:

- that wound infections were rapidly cleared;
- that additional antibiotics were not necessary;
- to prevent eminent (partial) DM foot amputation;
- to quickly debride wounds;
- to reduce wound size rapidly.

References

- Cooper R, Jenkins L (2009) A comparison between medical grade honey and table honeys in relation to antimicrobial efficacy. *Wounds* Feb 12, www.woundsresearch.com
- Dunford C, Cooper R, Molan P (2000) The use of honey in wound management. *Nurs Stand* 15(11): 63-8
- Du Toit D, Page B (2009) An in vitro evaluation of the cell toxicity of honey and silver dressings. *Journal of Wound Care* Volume 18(9): 383-389
- Molan P (2006) The evidence supporting the use of honey as a wound dressing. *Lower Extremity Wounds* 5(1): 40-54
- Muhammad Anwar Hau A (2008) National orthopedics diabetic hand and foot database (NODFD) *Med J Malaysia* 63(c): 75
- Postmes T, Van den Boogaard T, Hazen M (1993) Honey for wounds, ulcers and skin graft preservation. *The Lancet* Vol 341; March 20: 756-757
- Shukrimi A, Sulaiman A, Halim A, Azril A. (2008) A comparative study between honey and povidone iodine as dressing solution for Wagner type II diabetic foot ulcers. *Med J Malaysia* Mar; 63(1):44-6
- Yusof M, Sulaiman A, Muslim D (2007) Diabetic foot complications: a two-year review of limb amputation in a Kelantanese population. *Singapore Med J* 48 (8): 729

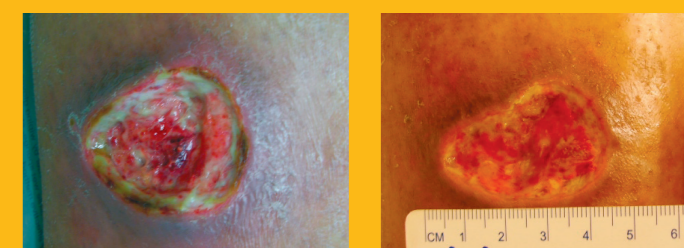
Fig. 1 Collated patient data

Case number:	C-084	C-085	C-086	0409	0509	0609
Age:	38	52	45	70	63	65
Sex:	Female	Male	Female	Female	Female	Male
Type of Diabetes:	2	2	2	1	2	2
Wound location:	left calf	left foot	left foot	left heel	left foot	left foot
Days the wound was present before L-Mesitran treatment:	14	85	13	-	7	28
Wound size in cm at the start (LxWxD):	4.5x2.8x1.0	3.0x3.0	1.8x1.8x0.3	4.0x4.0	2.0x1.5	4.5x2.5x3.0
Lab results for the type of infection:						
<i>Staph. aureus</i>	X			X		
<i>Ps. aeruginosa</i>		X				
<i>E. Coli</i>	X		X			
<i>Streptococcus B</i>			X		X	
Other ...						Gram +
Malodour at the start of treatment:	no	yes	no	no	no	yes
Were antibiotics used?	no	yes	no	no	no	no
After how many days was the malodour gone?	-	2	-	-	-	2
Time (in days) to control infection:	7	22	24	4	-	2
Time (in days) L-Mesitran was used:	44	36	43	45	15	14
Any pain during the treatment with L-Mesitran?	no	no	no	no	no	no
Wound size reduction:	95%	50%	n.a.	50%	n.a.	40%
Blood glucose level changes during L-Mesitran application:	no	no	no	no	no	no
Amputation indicated at the start of the treatment?	no	yes	yes	yes	yes	no
Amputation still indicated after L-Mesitran treatment?	no	no	no	no	no	no

Case C084: *Staph. aureus* & *E. Coli*

A 38 year old female with a deep, dirty wound with necrotic tissue on her left calf. The wound was very sloughy and produced yellow exudate. She was initially treated for 14days with oral antibiotics and incisions in the abscess, superoxidated solution and film dressings, with no effect. The wound was infected with *Staph. aureus* and *E. Coli*.

This infection was under control within a week of daily honey treatment, no additional antibiotics were used. In 44 days the wound had reduced from 12.6cm³ to 1.2cm³, a reduction of 95%.

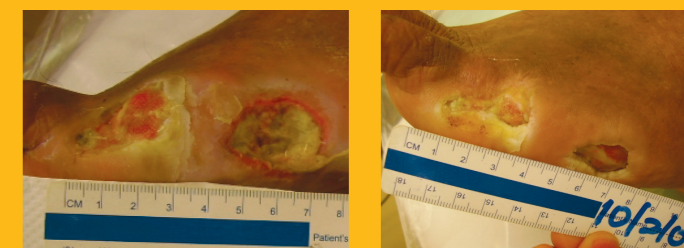


1. The start of the treatment 2. After 44 days of treatment

Case C085: *Pseudomonas aeruginosa*

A 52 year old male suffers from renal disease (end stage) and is on haemodialysis. After a ray amputation, the post-op wound did not heal and he also had a dirty sloughy ulcer lateral of 3cm x 3cm. The wound produced moderate yellow exudate. Cultures showed colonization with *Ps. aeruginosa*, resistant against amoxicillin and piperacillin/tazobactam.

The patient received instructions to do the honey dressing changes at home. The *Ps. aeruginosa* infection was successfully controlled in a 36 day period. Furthermore, the wound decreased 50% in size. Amputation of the foot was avoided, without any adverse reactions or influence on blood glucose levels.



1. Start of the treatment 2. After 36 days of treatment

Declaration of interest

This study was done independently by the authors.

L-Mesitran® is a registered trademark and is distributed in Malaysia by Jasmine Plus Health Care Sdn. Bhd. Kuala Lumpur. www.l-mesitran.com